



Symmetry

Facial Plane Relator



 Clinician's Choice Dental Products, Inc
167 Central Ave., London, ON Canada N6A 1M6
1.800.265.3444 • 519.641.3066 clinicianschoice.com

Rx only

1.800.265.3444
519.641.3066
www.clinicianschoice.com

Symmetry

Facial Plane Relator

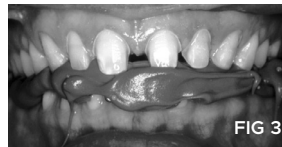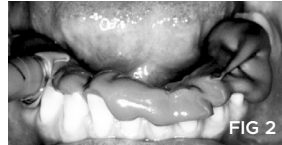

INTENDED USE: A tool to be used as a medical device for the purposes of recording an accurate bite registration and the exact position of the midline in relation to the horizontal plane.

CLINICAL INSTRUCTIONS

1. Assemble the Symmetry Facial Plane Relator by snapping the vertical alignment bar into the Facial Plane Relator arch (*fig 1*).

A marker can be used to make a fine line on the front of the cross for improved visibility.

2. With the patient in an upright position, apply a thick ribbon of Affinity Quick Bite across the upper arch (*fig 2, 3*).
3. At the same time, the dental assistant applies Affinity Quick Bite to the Facial Plane Relator arch fingers so they are completely covered, top and bottom (*fig 4*).
4. Instruct the patient to close in centric occlusion. When applied properly the excess material will extrude labially upon closure.



5. Immediately insert the Facial Plane Relator arch fingers into the extruded material, reminding the patient to stay closed (*fig 5*).

Adjust Symmetry Facial Plane Relator to align with the patient's face.

Please note: The patient does not bite on the Symmetry Facial Plane Relator arch. This is a closed bite technique.

Holding the arch in place, allow the material to cure. For additional support, more material may be applied to the arch while still in the closed position.

6. When complete, have the patient open and carefully remove the Symmetry Facial Plane Relator arch. Dislodge the vertical axis bar, protect it to prevent distortion, and send it to the laboratory with your final impression.

When properly used, Symmetry Facial Plane Relator will accurately communicate the patient's vertical and horizontal midlines to the laboratory technician. This will guide him/her in setting the proper angulation and the incisal edge position of the maxillary centrals, as well as the proper angulation of the occlusal plane (*fig 6*).

